

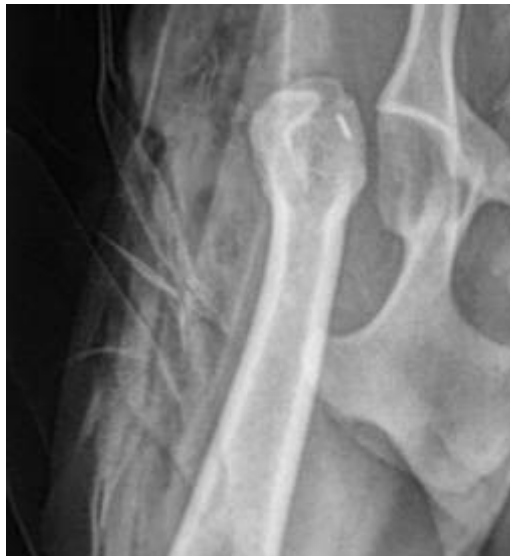## Femoral Head and Neck Osteotomy

### The Pet Health Care Library

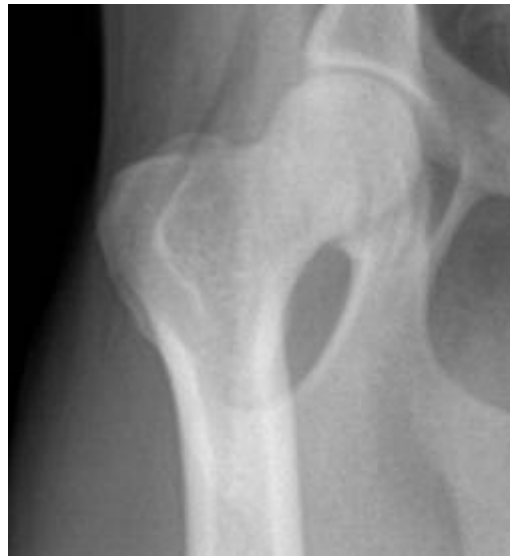There are many reasons why a pet might benefit from removing the femoral head and neck. Some typical reasons include:

- A dislocated hip
- A broken femoral head
- Hip arthritis
- Legg-Perthes disease (a developmental hip degeneration).

Ultimately, the goal of the femoral head and neck osteotomy (FHNO) surgery is to create a false hip joint that will be more comfortable and yield better mobility than the diseased joint the patient had before. Since results are generally so good with surgery, provided the patient is relatively small and/or relatively active, often simply removing the femoral head is the least invasive, least costly, and fastest route to a pain-free mobile hip.



*femoral head cut off after FHNO (radiograph courtesy of Mar Vista Vet)*



*normal hip (radiograph courtesy Mar Vista Vet)*


### The Normal Hip Joint

The hip joint is a ball and socket type joint that attaches the rear leg to the trunk of the body. The ball part is the head of the first long bone of the rear leg, called the femur, and the socket is the part of the pelvis known as the acetabulum. The femoral head is held in place by a thick ligament called the capital ligament, or simply the round ligament of the femoral head. Also keeping the bones in their proper location are the muscles of the hip; the upper rim of the acetabulum, which acts as a protective ledge; and the fact that the whole joint is enclosed in fibrous capsule.

When the femoral head is cut off, there is no more ball and socket, just basically an empty socket. The femur is kept in place by the leg muscles and eventually a fibrous connection forms what is called a false joint around the acetabulum and the area where the femur used to be. This fibrous false joint does not produce joint fluid and does not possess the normal cellular structures of a real joint, but it connects the bones together effectively.

### The Optimal Patient

The FHNO surgery is best done on a smaller patient, about 45 pounds or less. This is because a false joint simply is not strong enough to readily support the weight of a large dog, and mobility will likely be compromised. On the other hand, lots of activity strengthens the muscles and builds a stronger false joint so a very active larger patient may end up with better mobility than a less active smaller patient.



*Photo courtesy of morguefile.com*

## **Surgery**

As mentioned, surgery involves removing the femoral head under general anesthesia. Your pet will be in the hospital overnight on pain management medication and will go home when he has a good appetite and is mobile on three legs. The leg on the side of the surgery will be held off the ground. There may or may not be visible stitches. Recovery can be expected to take approximately SIX WEEKS.

## **The First Two Weeks after Surgery**

During this period, the tissues are healing from having been cut and manipulated during surgery. The focus is on pain management and rest. After the second day, warm (not lukewarm but very warm) compresses for 10 to 20 minutes are helpful to improve circulation to the area. This should be done two to six times daily.

If the patient will tolerate it, moving the hip forward and back (passive range of motion, or PROM) will help keep the muscles from becoming stiff or scarred. The entire leg should receive flexion/extension as shown in [this video](#).

Do not perform PROM if your dog is too painful. Try to keep the movements to a range that does not evoke pain. If you think your dog is in too much pain for any of this, notify your veterinarian so that the pain management regimen can be revised.

The pet should be confined indoors to one room during this period with no running or jumping onto furniture. Dogs should be walked on a leash outside to go to the bathroom and right back in with no further walks outside.

At the end of the first week, the foot should be touching down.

## **After the First Two Weeks**

At this stage, the post-operative pain has largely resolved and the goal is to strengthen muscle and prevent atrophy from disuse. The above exercises should be easily performed more definitively, plus other activities may be restarted: walking through water (better than swimming), walking (especially up stairs or uphill), and "dancing" (holding the pet up by his front legs and walking him on his hind legs). If the false joint forms too tightly, normal range of motion will not be regained so exercise is very important during this time.

Healing is generally complete after six weeks. This may be prolonged by arthritis in the other leg limiting activity, the size/weight of the patient, or long-standing scarring or atrophy of muscles from the initial condition that necessitated the FHNO in the first place. More formal rehabilitation programs can be designed for patients with these situations or who are behind schedule on their recovery for unknown reasons. If you have questions or concerns about your pet's recovery, let your veterinarian know at once so that your pet can get back on track for normal mobility.

---

Copyright 2014 - 2016 by the Veterinary Information Network, Inc. All rights reserved.

Permanent Link: <http://www.VeterinaryPartner.com/Content.plx?P=A&A=3575>